

A Gene for X-Linked Optic Atrophy Is Closely Linked to the Xp11.4-Xp11.2 Region of the X Chromosome

Jacqueline J. M. Assink,¹ Nel T. Tijmes,¹ Jacoline B. ten Brink,¹ Roelof-Jan Oostra,³ Frans C. Riemsdag,² Paulus T. V. M. de Jong,^{1,4,5} and Arthur A. B. Bergen¹

Departments of ¹Ophthalmogenetics and ²Visual System Analysis, The Netherlands Ophthalmic Research Institute, ³Department of Clinical Genetics, The Free University Hospital, and ⁴Department of Ophthalmology, Academic Medical Centre, Amsterdam; and ⁵Department of Epidemiology and Biostatistics, Erasmus University Rotterdam, Rotterdam

Summary

The aim of this study was to identify the chromosomal location of the disease-causing gene in a family apparently segregating X-linked optic atrophy. A large family of 45 individuals with a four-generation history of X-linked optic atrophy was reexamined in a full ophthalmic as well as electrophysiological examination. A DNA linkage analysis of the family was undertaken in order to identify the chromosomal location of the disease-causing gene. Linkage analysis was performed with 26 markers that spanned the entire X chromosome. The affected males showed very early onset and slow progression of the disease. Ophthalmic study of the female carriers did not reveal any abnormalities. Close linkage without recombination was found at the MAOB locus (maximum LOD score [Z_{\max}] 4.19). The $Z_{\max} - 1$ support interval was found at a recombination fraction of .076 distal and .018 proximal to MAOB. Multipoint linkage analysis placed the optic atrophy-causing gene in the Xp11.4-p11.21 interval between markers DXS993 and DXS991, whereas any other localization along the X chromosome could be excluded.

Introduction

Several inherited forms of atrophy of the optic nerve are known. Most common are dominant optic atrophy (DOA) and Leber hereditary optic neuropathy (LHON). In DOA the onset is in early childhood, if not congenital. Usually, DOA is a mild disease with slow progression. Nystagmus is commonly seen in DOA, and color vision is initially normal; later, when visual acuity decreases to $\leq .5$, a blue-yellow (tritan) defect is usually found (Kokvan Alphen 1970; Kjer 1972). A different type of DOA

is the mild form associated with hearing loss and even with ophthalmoplegia, ptosis, dystaxia, and a nonspecific myopathy (Treft et al. 1984; Meire et al. 1985). Some severe forms of DOA exist as well, although they are rare. The inheritance is autosomal dominant with varying expression. Recently, a gene implicated in DOA was mapped, in a Danish family, to the chromosome 3q region (Eiberg et al. 1994).

LHON is characterized by acute or subacute visual loss due to severe bilateral optic atrophy. Visual acuity, which is rapidly reduced in the acute stage of the disease, may occasionally improve somewhat in the chronic stage. Visual fields show a large central or centrocecal scotoma. The age at onset of visual impairment is usually 18–35 years. The inheritance in LHON is maternal and is associated with mtDNA mutations and is possibly influenced by an X-chromosomal factor (van Senus 1963; Wallace et al. 1988).

Aside from DOA and LHON, other hereditary forms of optic atrophy are rare. In contrast to DOA and LHON, in which the optic nerve is usually the only affected organ, the recessive optic atrophies are multi-systemic diseases; the CNS is affected along with the optic atrophy and other organs. Recessive optic atrophy includes Behr syndrome, Wolfram syndrome, and growth retardation, alopecia, pseudo-anodontia and optic atrophy syndrome (Behr 1909; Wolfram and Wagoner 1938; Tipton and Gorlin 1984).

Another form of hereditary optic atrophy is X-linked optic atrophy (XLOPT). So far, four distinct families with an apparent XLOPT have been described in the literature. The first apparent XLOPT was described by Lysen and Oliver (1947), who reported optic atrophy in eight males over four generations. Rosenberg and Chutorian (1967) described two brothers and their nephew who had optic atrophy, polyneuropathy, and deafness. Another family with three individuals with optic-acoustic nerve atrophy with dementia was described by Jensen et al. (1987). Finally, Völker-Dieben et al. (1974) and Went et al. (1975) described a large family with XLOPT. In the latter family, eight males had optic atrophy of early onset. Close linkage between the optic atrophy and Xg genes was excluded.

Received February 6, 1997; accepted for publication July 21, 1997.

Address for correspondence and reprints: Dr. A. A. B. Bergen, The Netherlands Ophthalmic Research Institute, Department of Ophthalmogenetics, P.O. Box 12141, 1100 AC Amsterdam, The Netherlands. E-mail: A.Bergen@ioi.knaw.nl

© 1997 by The American Society of Human Genetics. All rights reserved. 0002-9297/97/6104-0023\$02.00

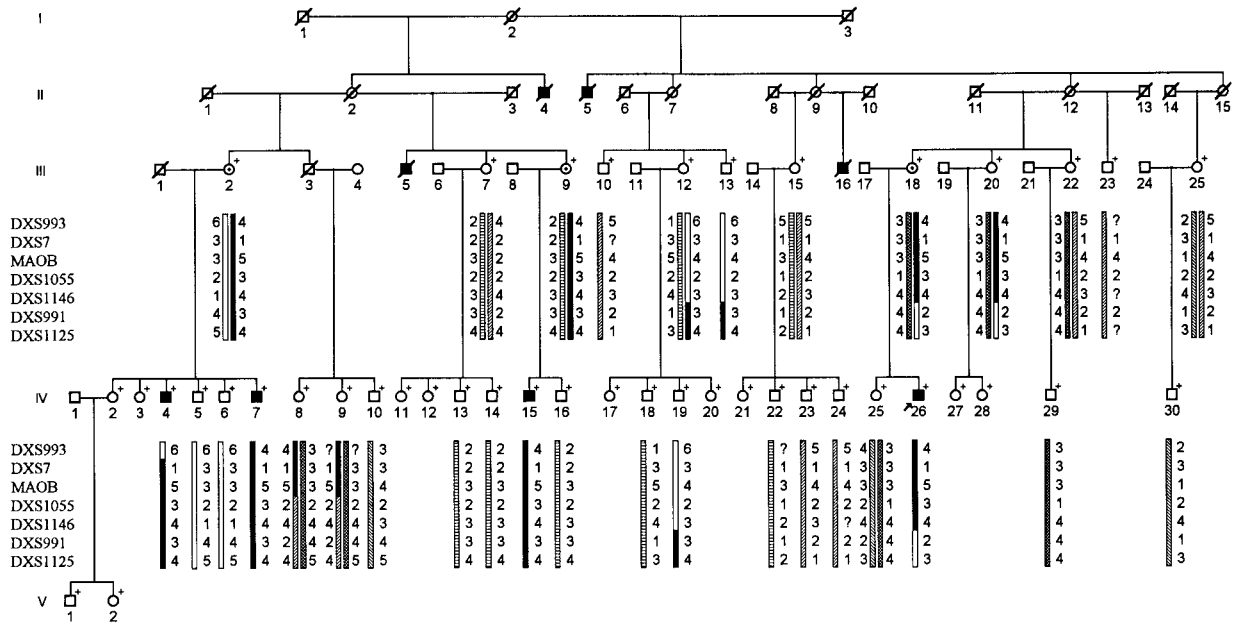


Figure 1 Pedigree of family with optic atrophy, showing segregation of X-chromosome loci. A plus sign (+) denotes that the individual was examined. Males are represented by squares, and females are represented by circles; blackened symbols represent individuals with optic atrophy, unblackened symbols represent normal individuals, and circles containing a black dot represent obligatory female carriers. The most likely haplotypes were constructed. The haplotype associated with the disease is marked by a solid bar.

In this study we reexamined the Dutch pedigree described by Völker-Dieben et al. (1974) and Went et al. (1975) in order to identify the presently affected and unaffected family members, for the purpose of DNA studies. Following ophthalmic examination, a linkage study was performed to localize a gene on the X chromosome involved in optic atrophy.

Subjects and Methods

The study was approved by the medical ethical committee of the Academic Medical Centre in Amsterdam. Informed consent was obtained from all study participants. In the linkage study, 45 individuals of this six-generation pedigree were included (fig. 1). Three individuals were seen at their homes, and therefore only visual acuity, eye movements, and indirect ophthalmoscopy were performed. The ophthalmic examination of the other individuals included Best refracted visual acuity, eye movements, pupillary-reflex testing, and biomicroscopy. Color vision was tested with the Farnsworth-Munsell D15 Hue test and the Ishihara test. Tonometry was performed by the Goldmann applanation method. Visual evoked potentials were measured in all individuals, with a pattern-reversal chessboard and flash stimulation. After pupillary dilation, retinoscopy and indirect ophthalmoscopy were performed. Fundus transparencies were taken with a Topcon VT 50 camera. In order to exclude the possibility of neuroepithelial dysplasia

leading to antegrade optic atrophy, an electroretinogram was performed according to standards of the International Society for Clinical Electrophysiology of Vision, on the proband (IV-26) of this family.

Blood samples from all individuals were obtained. Standard techniques were used to extract DNA, and PCR and CA-repeat analyses were performed as described elsewhere (Bergen et al. 1991). Because the pedigree data were compatible with maternal inheritance, we investigated the presence of LHON-associated mtDNA mutations at nucleotide positions 3460, 9438, 9804, 11778, 14484, and 15257 in the DNA of the proband (IV-26), his sister (IV-25), and his mother (III-18). Initially, linkage analysis was performed with 20 CA-repeat markers derived from evenly spaced regions of the X chromosome (see table 1). After we found positive LOD scores (Z), additional markers were used to mark the gene location more precisely. The data were analyzed with the program package LINKAGE, version 5.1. Two-point Z values were calculated with the program MLINK, and multipoint analyses were conducted with the program LINKMAP. The fixed order and genetic distances were set as follows: DYSI-.07-JL152-.01-DXS993-.01-DXS228-.01-MAOB-.03-DXS1055-.01-DXS1146-.09-DXS991-.04-DXS1125-.08-DXS453. Penetrance values for obligatory carriers and normal appearing males were set at .00. An optic atrophy gene frequency of .00001 was used.

Table 1**Two-Point Z Values for Linkage between Liability to Develop Optic Atrophy and 26 X-Chromosomal Marker Loci**

LOCUS (LOCATION)	Z AT $\theta =$						
	.0	.01	.05	.1	.2	.3	.4
KAL (p22.3)	−∞	−2.89	−.96	−.27	.19	.28	.19
DXS207 (p22.2)	−∞	−3.55	−1.52	−.72	−.08	.14	.14
DXS365 (p22.1)	−∞	−2.58	−1.26	−.75	−.32	−.12	−.03
DYSI (p21.2)	−∞	−2.62	−1.29	−.76	−.31	−.11	−.02
JL152 (p21.1)	−∞	−1.95	−.68	−.25	−.04	.09	.07
DXS993 (p11.4)	−∞	1.70	2.16	2.14	1.78	1.26	.65
DXS228 (p11.4)	1.96	1.92	1.75	1.54	1.12	.70	.31
DXS7 (p11.4)	3.51	3.45	3.21	2.89	2.23	1.51	.76
MAOB (p11.4)	4.19	4.13	3.87	3.53	2.79	1.96	1.04
DXS1055 (p11.3)	2.19	2.13	1.90	1.61	1.00	.43	.07
DXS1146 (p11.3)	2.47	2.43	2.24	2.01	1.53	1.04	.53
DXS991 (p11.2)	−3.03	.71	1.28	1.41	1.31	.99	.53
DXS1125 (q11.2)	−2.63	1.04	1.61	1.73	1.57	1.18	.64
DXS453 (q13.1)	−∞	2.26	2.75	2.76	2.39	1.78	.99
DXS441 (q13.2)	2.50	2.47	2.34	2.15	1.73	1.23	.66
DXS1002 (q21.3)	−2.99	.80	1.32	1.38	1.21	.90	.49
DXS456 (q22.1)	−∞	−3.45	−1.38	−.56	.06	.20	.13
DXS1106 (q22.1)	−∞	−3.19	−1.22	−.49	.03	.15	.09
DXS994 (q24)	−∞	.47	1.00	1.09	.94	.64	.31
DXS1114 (q26.1)	−∞	−3.79	−1.61	−.75	−.11	.05	.04
DXS984 (q27.1)	−∞	.04	.59	.71	.64	.45	.21
VK23 (q27.2)	−∞	−.52	.06	.23	.26	.19	.10
DXS1123 (q28)	−∞	−2.32	−1.01	−.52	−.15	−.01	.02
DXS1113 (q28)	−∞	−4.15	−2.12	−1.30	−.58	−.24	−.07
F8C (q28)	.30	.29	.24	.19	.10	.05	.02

Results

The two patients in the second generation (II-4 and II-5) and the two patients in the third generation (III-5 and III-16) had died since the studies by Völker-Dieben et al. (1974) and Went et al. (1975). After the reexamination of all other individuals, we confirmed that individuals IV-4, IV-7, IV-15, and IV-26 have optic atrophy. No newly affected persons were identified. All other individuals were found to be unaffected. The assignment of carrier status was based on the fact that a carrier has an affected son. Ophthalmic study of the obligate female carriers did not reveal any abnormalities.

Those affected had visual acuities of .02–.25 and severe bilateral optic atrophy. The age at onset was in early childhood, and the progressive loss of visual acuity was very slow. Their disks were sharply outlined and completely pale, and no microaneurysmata or microangiopathies were seen. The macula and the periphery of the retina showed no abnormalities. They had no nystagmus and had no disturbance of their night vision by anamnesis. Their color-vision tests showed strong defects, but no blue-yellow defects could be detected. The visual evoked potentials of the affected males resulted

in prolonged latencies. The electroretinogram of the proband showed no abnormalities. The fundus transparencies of all cases were independently graded by three investigators, on paleness of the disk and delineation of its margins. The results of the ophthalmic examination of the affected males are presented in table 2. A noteworthy detail is that none of the affected males had any children. Two of the deceased affected males (II-4 and III-16) and two living affected males (IV-7 and IV-15) did not have wives, whereas the other four affected males were married.

None of the mtDNA mutations that we tested for was found in either one of the investigated individuals. Subsequently, the pedigree was studied with 26 markers from the X chromosome. The pedigree of the family in figure 1 shows the segregation of X-chromosome loci from the proximal Xp. The most likely haplotypes were manually constructed. Although, on the basis of her haplotype, individual III-20 could be a carrier, we neither assigned her as a carrier nor took her into account for linkage-analysis purposes. In individual IV-4, recombination occurs that suggests that the location of the optic atrophy locus is proximal to DXS993, whereas the recombination event revealed by the haplotype of III-18

Table 2**Ophthalmological Findings in Four Patients with Optic Atrophy**

PATIENT	AGE ^a (years)	VISUAL ACUITY		OPHTHALMOSCOPY ^b		COLOR VISION	VISUAL EVOKED POTENTIAL
		Right Eye	Left Eye	Right Eye	Left Eye		
IV-4	20	.2	.2				
	43	.02	.02	Strong defects, no blue-yellow defect	No pattern responses, flash responses right eye and left eye
IV-7	12	.4	.3				
	36	.13	.13	Strong defects, no blue-yellow defect	Prolonged latencies, right eye and left eye = 127 ms
IV-15	17	.3	.3				
	41	.13	.13	Not tested	Not tested
IV-26	9	.1	.2				
	33	.13	.25	Deutan defect, no blue-yellow defect	Prolonged latencies, right eye and left eye = 125 ms

^a For each patient, the first entry is the age at the time of the investigations by Völker-Dieben et al. (1974) and Went et al. (1975), and the second entry is the age at the time of the present study.

^b An ellipsis indicates that there were no abnormalities except for pale optic disk.

and IV-26 places the optic atrophy locus distal to DXS991. Two-point linkage data on the XLOPT locus and the markers are shown in table 1. Close linkage without recombination was found between the XLOPT gene and each of the markers from the Xp11.4-p11.2 region: DXS228, DXS7, MAOB, DXS1055, and DXS1146.

Only one additional significantly positive two-point Z value was found with a marker (DXS441) from the Xq13 region. However, recombination analysis and multipoint linkage analysis excluded a localization of XLOPT near DXS441, between DXS453 and DXS1002 (data not shown). Thus, the positive Z value is due to the differential informativeness of DXS441 in this family. Multipoint linkage analysis placed the optic atrophy-causing gene with a $Z_{\max} - 1$ support interval at recombination fraction (θ) values of .076 distal and .018 proximal to MAO-B. All other possibilities along the X chromosome were excluded. The multipoint linkage analyses are shown in figure 2.

Discussion

In this paper we have reported a family with an optic nerve atrophy that is different from the more common types of optic atrophy. Clinically, DOA is the most comparable optic atrophy. Both disease entities have an early onset and slow progression. In DOA, nystagmus and blue color-vision defects have been described, although they are not obligatory. No nystagmus or blue-yellow defects were found in this family. The optic atrophy in this family differs from LHON, especially with respect to the early age and mode of onset (table 2). Furthermore, in contrast to our family, the visual impairment

in LHON is nonprogressive after the acute phase. The recessive optic atrophies, as well as the other XLOPTs are also very distinct from the disease in this family. The Jensen syndrome is an optic atrophy with dementia, and the Rosenberg-Chutorian syndrome is an optic atrophy with hearing loss. In the family described by Lysen and Oliver (1947) also, chorioretinitis, congenital nystagmus, secondary cataract, and a beginning of a phthisis of the globe are reported in addition to optic atrophy (Völker-Dieben et al. 1974). Genetically, there is a difference between DOA and the optic atrophy that we have described. In DOA, although variable expression

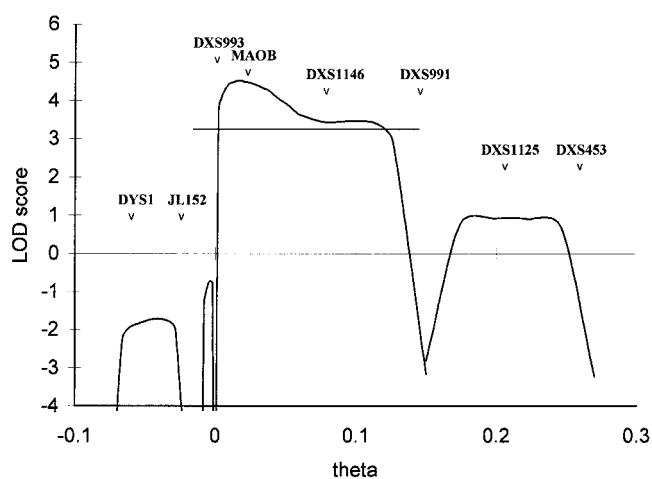


Figure 2 Multipoint likelihoods for location of optic atrophy locus on X chromosome. A location of the optic atrophy locus between DXS993 and DXS991 is favored over an alternative position by odds $>4,450:1$. The horizontal line in the graph represents the $Z_{\max} - 1$ support interval for the location.

of the disease occurs, males and females are affected in equal numbers, whereas in our family only males are affected and females do not reveal any abnormalities. Similarly to LHON, the disease seems to be maternally inherited. However, the clinical history is not consistent with an LHON phenotype, and the index case in our family had no LHON-associated mtDNA mutations. In addition, in this family we have assigned the optic atrophy-causing gene to the Xp11.4–Xp11.2 region. To our knowledge this is the first family with optic atrophy in which a presumed X-linked inheritance is supported by the results of linkage studies. The region of the X chromosome identified contains also the genes involved in retinitis pigmentosa type 2, congenital stationary night blindness type 2, and Norrie disease. It may be well worth investigating whether mutations in these genes could be involved in XLOPT.

Although LHON is a maternally inherited disease associated with mtDNA mutations, some features of the disease cannot be explained simply by mitochondrial inheritance alone; there is an excess of males affected by LHON, with a commonly found male:female ratio of 5.6:1, and most of the carriers of LHON-specific mtDNA mutations remain unaffected (van Senus 1963; Black et al. 1995; Oostra et al. 1996). It has been suggested that the peculiar inheritance pattern of the disease could be the result of an interaction between an X-linked gene and an mtDNA defect (van Senus 1963; Wallace et al. 1988; Bu and Rotter 1991). However, linkage studies have been negative (Chen et al. 1989; Villki et al. 1991; Carvalho et al. 1992; Sweeney et al. 1992; Juvonen et al. 1993). The localization of an X-linked disease-causing gene in XLOPT could have important implications for the pathogenesis of LHON and other optic atrophies as well.

Acknowledgments

The authors would like to thank Dr. P. A. Bolhuis (Department of Neurology, Academic Medical Centre, Amsterdam) for investigating the presence of LHON-associated mtDNA mutations. We gratefully acknowledge Dr. H. J. Völker-Dieben and Prof. Dr. L. N. Went for providing the genealogical data. Finally, we are grateful to L. Appel and A. Frens for performing the visual evoked-potential test and the electroretinogram.

References

Behr C (1909) Die komplizierte, hereditär-familiäre Optikusatrophie des Kindesalters: ein bisher nicht beschriebener Symptomenkomplex. *Klin Monatsbl Augenheilkd* 47:138–160
 Bergen AAB, Samanns C, Schuurman EJM, van Osch L, van Dorp DB, Pinckers AJLG, Bakker E, et al (1991) Multipoint linkage analysis in X-linked ocular albinism of the Nettleship-Falls type. *Hum Genet* 88:162–166

Black GCM, Craig IW, Oostra RJ, Norby S, Morten K, Laborde A, Poulton J (1995) Leber's hereditary optic neuropathy: implications of the sex-ratio for linkage studies in families with the 3460 ND1 mutation. *Eye* 9:513–516
 Bu XD, Rotter JI (1991) X Chromosome-linked and mitochondrial gene control of Leber hereditary optic neuropathy: evidence from segregation analysis for dependence on X-chromosome inactivation. *Proc Natl Acad Sci USA* 88:8198–8202
 Carvalho MR, Muller B, Rotzer E, Berninger T, Kommerell G, Blankenagel A, Savontaus ML, et al (1992) Leber's hereditary optic neuropathy and the X-chromosomal susceptibility factor: no linkage to DXS7. *Hum Hered* 42:316–320
 Chen JD, Cox I, Denton MJ (1989) Preliminary exclusion of an X-linked gene in Leber optic atrophy by linkage analysis. *Hum Genet* 82:203–207
 Eiberg H, Kjer B, Kjer P, Rosenberg T (1994) Dominant optic atrophy (OPA1) mapped to chromosome 3q region. I. Linkage analysis. *Hum Mol Genet* 3:977–980
 Jensen PKA, Reske-Nielsen E, Hein-Sørensen O, Warburg M (1987) The syndrome of opticoacoustic nerve atrophy with dementia. *Am J Med Genet* 28:517–518
 Juvonen V, Vilkkki J, Aula P, Nikoskelainen E, Savontaus ML (1993) Reevaluation of the linkage of an optic atrophy susceptibility gene to X-chromosomal markers in Finnish families with Leber hereditary optic neuropathy (LHON). *Am J Hum Genet* 53:289–292
 Kjer P (1972) Infantile optic atrophy with dominant mode of inheritance. In: Vinken PJ, Bruyn GW (eds) *Handbook of clinical neurology*. North Holland Publishing Company, Amsterdam, pp 111–123
 Kok-van Alphen CC (1970) Four families with the dominant infantile form of optic nerve atrophy. *Acta Ophthalmol* 48:905–916
 Lysen JC, Oliver CP (1947) Four generations of blindness. *Bull Dight Inst* 5:20–25
 Meire F, De Laey JJ, de Bie S, van Staey M, Matton MT (1985) Dominant optic nerve atrophy with progressive hearing loss and chronic progressive external ophthalmoplegia (CPEO). *Ophthalmic Paediatr Genet* 5:91–97
 Oostra RJ, Kemp S, Bolhuis PA, Bleeker-Wagemakers EM (1996) No evidence for 'skewed' inactivation of the X-chromosome as cause of Leber hereditary optic neuropathy in female carriers. *Hum Genet* 97:500–505
 Rosenberg RN, Chutorian A (1967) Familial opticoacoustic nerve degeneration and polyneuropathy. *Neurology* 17:827–832
 Sweeney MG, Davis MB, Lashwood A, Brockington M, Toscano A, Harding AE (1992) Evidence against an X-linked locus close to DXS7 determining visual loss susceptibility in British and Italian families with Leber hereditary optic neuropathy. *Am J Hum Genet* 51:741–748
 Tipton RE, Gorlin RJ (1984) Growth retardation, alopecia, pseudo-anodontia, and optic atrophy—the GAPO syndrome: report of a patient and review of the literature. *Am J Med Genet* 19:217–223
 Treft RL, Sanborn GE, Carey J, Swartz M, Crisp D, Wester DC, Creel D (1984) Dominant optic atrophy, deafness, ptosis, ophthalmoplegia, dystaxia, and myopathy: a new syndrome. *Ophthalmology* 91:908–915

- van Senus AHC (1963) Leber's disease in the Netherlands. *Doc Ophthalmol* 17:1–162
- Vilkki J, Ott J, Savontaus M-L, Aula P, Nikoskelainen EK (1991) Optic atrophy in Leber hereditary optic neuroretinopathy is probably determined by an X-chromosomal gene closely linked to DXS7. *Am J Hum Genet* 48:486–491
- Völker-Dieben HJ, van Lith GHM, Went LN, Klawer JW, Staal A, de Vries-de Mol EC (1974) A family with sex linked optic atrophy. *Doc Ophthalmol* 37:307–326
- Wallace DC, Singh G, Lott MT, Hodge JA, Schurr TG, Lezza AMS, Elsas LJ, et al (1988) Mitochondrial DNA mutation associated with Leber's hereditary optic neuropathy. *Science* 242:1427–1430
- Went LN, de Vries-de Mol EC, Völker-Dieben HJ (1975) A family with apparently sex-linked optic atrophy. *J Med Genet* 12:94–98
- Wolfram DJ, Wagener HP (1938) Diabetes mellitus and simple optic atrophy among siblings: report of four cases. *Proc Staff Meet Mayo Clin* 13:715–718